

## CHAPTER 1

### INTRODUCTION

#### 1.1 Rationale

Lumbopelvic stability (LPS) can be explained based on the neuromuscular control required around the lumbar spine to maintain functional stability and protect the spine from injury <sup>(1, 2)</sup>. The spinal stability model incorporates the three components: a passive system like a vertebral and spinal ligament, an active system like the trunk muscle capacity and the neural control system which coordinate passive and active subsystems <sup>(3, 4)</sup>. Failure to incorporate this stability model may induce lumbopelvic instability, which is a common cause of recurrent and chronic low back pain (LBP).

The motor control of spinal stabilization training has been developed and commonly used for LBP treatment <sup>(3, 5-7)</sup>. The motor control of spinal stabilization focuses on the function of deep spinal muscles because these structures are thought to have the ability to control motion between vertebral segments. The motor control approach emphasizes that subjects learn to preferentially activate the deep trunk muscles <sup>(3)</sup>, primarily the transversus abdominis (TrA) and lumbar multifidus (LM) muscles. Many studies have highlighted the role of TrA and LM muscles in control of the spinal segment's neutral zone, provision of segmental stiffness and capacity to stabilize the spine <sup>(8-11)</sup>.

Several clinical assessments of deep muscle performance can be performed to guide clinical intervention. Electromyography (EMG) has traditionally been used to assess the TrA and LM magnitude and activity but the invasiveness of these procedures limits their routine clinical use<sup>(7, 12)</sup>. There are evidences supporting the use of ultrasound imaging as a noninvasive tool to assess deep muscle function<sup>(13-16)</sup>. The application of ultrasound imaging for the purposes of biofeedback and muscle performance measurement by rehabilitation professionals has been named rehabilitative ultrasound imaging (RUSI)<sup>(17, 18)</sup>. The most common parameter measurable with RUSI that relates to muscle activation is a change in muscle thickness. Several researchers have utilized thickness change as an indicator of muscle activation for the TrA<sup>(7, 19-21)</sup> and LM muscles<sup>(22, 23)</sup>. In addition, LM cross-sectional area (CSA) can be measured by ultrasound imaging and used to compare between different population<sup>(24, 25)</sup>. The validity of utilizing muscle thickness change as a measurement of lower level muscle activation has been demonstrated in the TrA<sup>(14, 26)</sup> and LM<sup>(16)</sup> in an asymptomatic population and for the TrA in subjects with LBP<sup>(19)</sup>. Researchers have used RUSI to demonstrate segmental decreased in the CSA of the LM, ipsilateral to painful symptoms in patients with LBP<sup>(25, 27)</sup>.

Adequate LPS is contributed to athletic performance by aiding in the efficient transmission of force generated by the lower body through the trunk to the upper body. Enhancing LPS may be associated with athletic performance<sup>(8)</sup>.

Weightlifting, a sport that exposes the athletes to extreme force during the training and competitive events, may cause instability to the spine and LBP<sup>(28, 29)</sup>. Injury survey conducted among weightlifters showed that the incidence of LBP was 23.1% in elite United State male weightlifters<sup>(30)</sup> and 28.89% in Thai weightlifters<sup>(31)</sup>.

Recently, prevalence of LBP was increased to 41.67% in elite Thai weightlifters <sup>(32)</sup>. Lumbopelvic instability is one of the problems found in patients with recurrent and chronic LBP <sup>(21, 33)</sup>, that associated with impairments in neuromuscular control of the deep musculature of the spine especially TrA and LM muscles <sup>(3, 34)</sup>. Researchers have demonstrated that impairments in these deep muscles, including atrophy <sup>(25, 35)</sup>, delayed activation <sup>(19, 36)</sup> and a lack of volitional control <sup>(13, 20)</sup>, are presented in

However, the characteristic of trunk muscles and its adaptation to back pain have never been investigated in weightlifters. The present study was conducted on elite Thai weightlifters attending the national training camp. Understanding the role of trunk muscles may guide effective LPS program to enhance lifting performance in weightlifters.

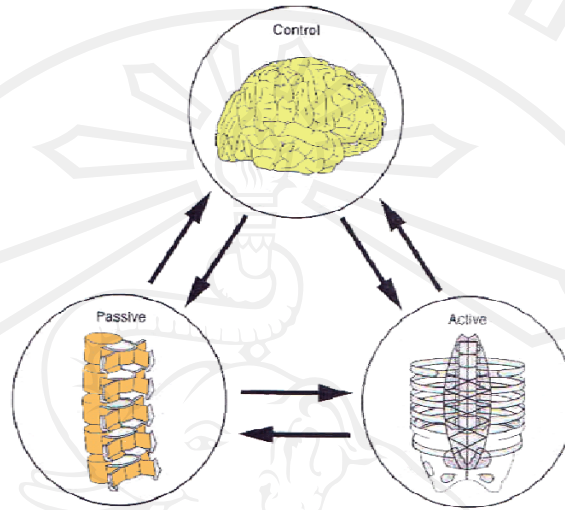
## **1.2 Background**

### **1.2.1 Lumbopelvic stability**

Concept of lumbopelvic stability (LPS) can be explained based on the spinal stability model (Figure 1-1). The stability model incorporates the three components: a passive system like a vertebral and spinal ligament, an active system like the trunk muscle capacity and the neural control system which coordinate passive and active subsystems <sup>(3, 4)</sup>. The failure to incorporate this stability model induces lumbopelvic instability, which is a common cause of recurrent and chronic LBP.

Active subsystem plays an important role for LPS. All core muscles are needed for optimal stabilization and performance <sup>(1)</sup>. However, it was found that TrA and LM muscles played a dominant role in stabilization mechanism <sup>(1-4, 37)</sup>.

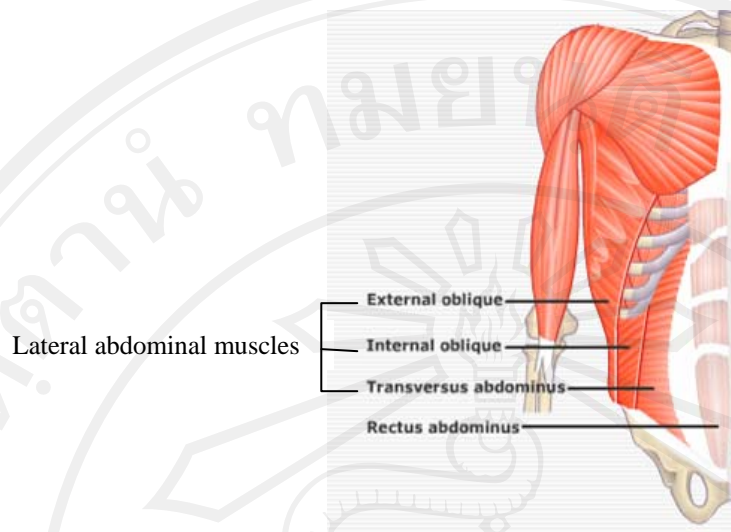
Dysfunction of TrA and LM may lead to spinal instability and resulted in an increase of the incidence of LBP<sup>(38, 39)</sup>.



**Figure 1-1** Spinal stability model<sup>(3, 4)</sup>

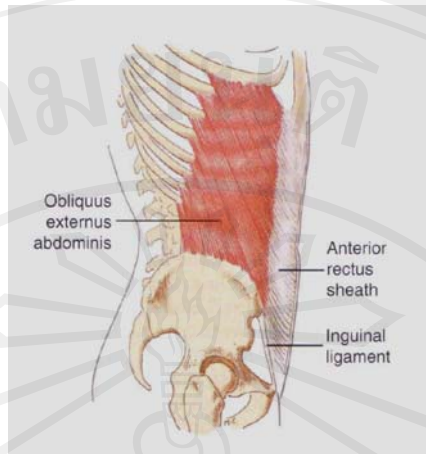
### 1.2.2 Lateral abdominal muscles function

Lateral abdominal muscles (LAM) refer to external oblique (EO), internal oblique (IO) and TrA muscles (Figure 1-2). LAM are important for control and movement of the lumbopelvis<sup>(40, 41)</sup>. These LAM have fibro-osseous attachments to the costal cartilages, the lumbar spine via the thoracolumbar fascia (TLF), the iliac crest and pubis<sup>(3, 37, 42)</sup>.



**Figure 1-2** Lateral abdominal muscles include external oblique, internal oblique and transversus abdominis muscles <sup>(43)</sup>

EO muscle is the most superficial of LAM. Its origin arises via lateral surface and lower margin of eight ribs (Figure 1-3). The upper five segments interdigitate with serratus anterior. The muscle fibers of EO descend in various directions, with the most inferior fibers directed almost vertically down to insert on the anterior part of iliac crest. The middle and upper fibers descend downwards and forwards to the anterior aponeurosis, interlacing with the aponeurosis of the opposite muscles to form the linea alba. The inferior regions of the aponeurosis are thickened and form the inguinal ligament. EO muscle has no attachment to TLF. The major functions of EO muscle are trunk flexion, contralateral trunk rotation and ipsilateral flexion <sup>(3)</sup>.

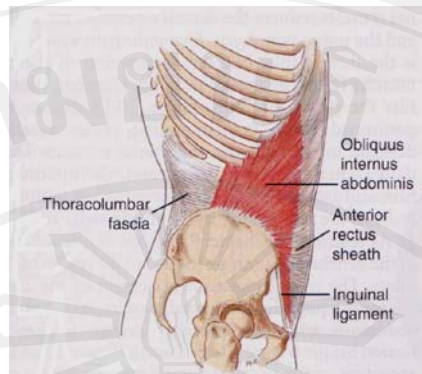


**Figure 1-3** External oblique muscles <sup>(44)</sup>

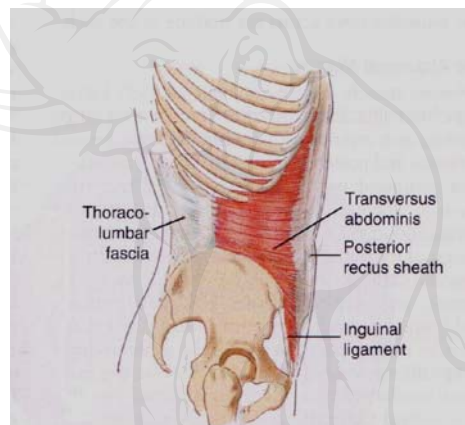
IO muscle forms the middle layer of the lateral abdominal wall. IO muscle attaches to the lateral two-thirds of the inguinal ligament, the anterior two-thirds of the iliac crest, and the lateral raphe of the TLF (Figure 1-4). The posterior iliac fibers pass superiorly to attach to the inferior border of the lower three or four ribs and are continuous with the internal intercostals muscles. The inferior fibers from the inguinal ligament run inferomedially and attach to the pubic crest as the conjoint tendon with TrA. The middle fibers diverge from the origin, ending in a bilaminar aponeurosis which with the upper fibers of the aponeurosis attaching to the outer surface of the 7<sup>th</sup> to 9<sup>th</sup> costal cartilages. The anterior fibers are continuous with the contralateral EO muscle while the posterior fibers are continuous with TrA. These EO fiber orientation will be coupled with the production of trunk movement, ipsilateral trunk rotation and ipsilateral trunk flexion. In addition, the lower fibers of IO muscle can compress the sacro-iliac joint and contribute to the force closure mechanism. In a small proportion of individuals, the posterior fibers of IO muscle insert into the lateral raphe of the TLF, which can transmit force to the TLF <sup>(3)</sup>.



TrA muscle is the deepest layer of abdominal muscles. TrA muscle originates from inner surface of lower six ribs, anterior two-thirds of medial lip of iliac crest, lateral thirds of inguinal ligament and lateral raphe of TLF (Figure 1-5). It also attaches to transverse process of first four or five lumbar vertebrae through TLF. TrA muscle passes medially to the linea alba. TrA muscle can be divided into three regions. Fibers of the upper region are rostral to the inferior border of the rib cage. These fibers have the most transverse orientation but have the shortest fiber length and are thinner than other regions. The middle fibers which pass between rib cage and iliac crest are those with only direct attachment to the TLF. These fibers are orientated significantly inferomedially and have the longest fiber length. The lower fibers from the iliac crest and inguinal ligament generally extend inferiorly to two-thirds of the distance between the iliac crest and pubic symphysis, are the most inferomedially oriented and thickest. When TrA muscle contracts bilaterally, it reduces the circumference of the abdominal wall and flattens the abdominal wall in the lower region to increase the intra-abdominal pressure (IAP) and tension in the TLF and anterior fascias. TrA muscle has a limited ability to generate trunk motion, although it is active during rotation efforts. Therefore, TrA muscle is considered to have its major effects on LPS via an increase in IAP and TLF tension and via compression of the sacro-iliac joints and pubic symphysis. <sup>(3, 45)</sup>.



**Figure 1-4** Internal oblique muscles <sup>(44)</sup>



**Figure 1-5** Transversus abdominis muscles <sup>(44)</sup>

Evidence for a contribution of TrA to LPS can come from two sources<sup>(45)</sup>. Firstly, from direct investigation of the ability of TrA to contribute to lumbopelvic control. Fire-wire EMG was successfully used to evaluate TrA activity. It was founded that TrA had unexpected continuous activity and had close relationship to IAP. TrA may contribute to a general mechanism for trunk stabilizer than the production of torque or control of orientation of the spine and as a possible contributors to spinal control via increase IAP <sup>(11, 40, 41, 45-47)</sup>. Secondly, by indirect investigation of how TrA is used by the central nervous system (CNS) during specific



tasks. In the limb movement and trunk loading studies, the response of TrA was consistent with a role of increasing the stiffness of the intervertebral joint<sup>(11, 39, 41, 45, 46, 48)</sup>. TrA was consistently the first muscle activated at the same latency prior to limb movement irrespective of movement direction. Since the onset of activation of TrA muscle preceded that of the muscle responsible for limb movement, it must be pre-programmed by the CNS<sup>(45)</sup>.

The TrA muscle has been found to contract in preparatory period prior to limb movements and spinal loading in individuals without low back pain<sup>(48)</sup>. The contraction was delayed in those with low back pain and failed to occur in the preparatory period before movement in all directions<sup>(19, 36, 39)</sup>. Previous studies concluded that a change in TrA activation was not simply a delay, but a dysfunction in its motor control<sup>(19, 36, 39, 48)</sup>.

Although, there is an increasing evidence to indicate the importance of LAM in the control of LPS, quantitative investigation of the LAM is minimal.

Urquhart et al<sup>(42)</sup> measured the orientation, thickness and length of the upper, middle and lower fascicles of TrA, IO and EO in 26 embalmed human cadavers. The mean vertical dimension of TrA that attached to the lumbar spine via the TLF was  $5.2 \pm 2.1$  cm. Intramuscular septa were observed between regions of TrA. IO could be separated into two distinct layers in the lower and middle regions. This study provides quantitative data of morphological differences between regions of the abdominal muscles, which suggests variation in function between muscle regions. Precise understanding of abdominal muscle anatomy is required for incorporation of these muscles into biomechanical models. Furthermore, regional variation in their morphology may reflect differences in functions.

Ultrasonography has been used to measure changes in muscle architectural during static and dynamic contractions <sup>(7, 13-15)</sup>. Because these architectural parameters often change markedly with contraction, recent attempts have been made to use changes in muscle size and thickness measured by ultrasound imaging to detect or measure muscle “activity”<sup>(15, 16, 49, 50)</sup>.

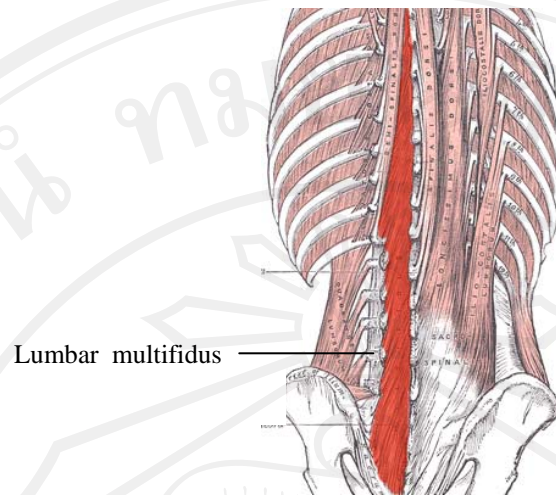
Hodges et al <sup>(14)</sup> compared ultrasonographic measures of muscle architectural with EMG activities. Subjects performed isometric contractions from 0 to 100% maximal voluntary contractions (MVC). Measurements of EMG and muscle architecture were made when the muscle relaxed and during contractions. Correspondingly, during isometric contractions, the relationship between ultrasound measurements and EMG or force is relatively linear at low forces, but plateaus with contraction greater than 20% MVC. A strong relationship has been found between activity of TrA and IO, and changes in muscle thickness. In contrast, no relationship between activity and morphological changes in EO has been found. Thus, RUSI can provide a non-invasive method of detecting isometric muscle contractions of certain individual muscles.

Teyhen et al <sup>(7)</sup> demonstrated that ultrasound imaging provided reliable measurement in muscles thickness. The result demonstrated that intrarater reliability for measuring lateral abdominal muscles thickness exceeded 0.93. The low back pain patients demonstrated average a 2-fold increase in the thickness of the TrA during the abdominal drawing-in maneuver (ADIM).

### 1.2.3 Lumbar multifidus muscle function

The LM muscle is the deepest and most medial lumbar muscles. LM muscle has vertebra –to-vertebra attachments within the lumbar and between the lumbar and sacral vertebra<sup>(3, 51)</sup>. LM muscle has five bands that arise from the spinous process and lamina of each lumbar vertebra and descend in a caudo-lateral direction (Figure 1-6). In band consists of series of fascicles, the superficial fascicle arises from spinous process and the deepest fascicle arises from the lamina. The most superficial fibers cross up to five segments and attach caudally to the iliac and sacrum, whereas the deep fibers attach from the inferior border of a lamina and cross a minimum of two segments to attach on the mamillary process and facet joint capsule. The superficial fibers are distant from the centers of rotation of the lumbar vertebrae, have an extension moment arm, and can control the lumbar lordosis. By contrast, the deep fibers have a limited moment arm and a minor ability to extend the spine<sup>(51, 52)</sup>.

LM muscles play an importance role in segmental stabilization of the lumbar spine. In asymptomatic subjects, LM muscle size increased on progression from L2 to L5<sup>(53, 54)</sup> Several imaging studies reported evidence of LM muscle atrophy in patients with LBP<sup>(23, 25, 35, 55-57)</sup>. However, no reports were found in athletes such as weightlifters who suffered from LBP.



**Figure 1-6** Lumbar multifidus muscles <sup>(58)</sup>

#### 1.2.4 Ultrasound imaging measurement

Ultrasound imaging is a radiological tool that has been widely used and continuing developed over several decades. Real-time ultrasound imaging is currently used extensively in medicine. It provides a safe, cost-effective and readily accessible method of examination of various organs and tissues. One area where ultrasonography has proved to be useful is investigation of musculoskeletal pathology. Tissues that can be imaged include muscles, tendons, joints, ligaments and bursa. The accuracy of ultrasonography in evaluating various conditions of the musculoskeletal system has been demonstrated and its utility as a primary diagnostic imaging modality in the musculoskeletal system is increasing in frequency <sup>(59)</sup>. One of the most useful features of real-time ultrasound imaging is that movement of anatomical structures can be observed as it actually occurs. This allows development of a new application of real-time ultrasound imaging for clinical physiotherapy rehabilitation (rehabilitative ultrasound imaging: RUSI) that involves observation of muscle contraction to provide feedback and assessment of muscle function <sup>(17, 18, 24)</sup>.

RUSI related to musculoskeletal rehabilitation has been ongoing since 1995<sup>(24)</sup>, and investigation has been established<sup>(60)</sup>. Ultrasound imaging is a safe, cost-effective, and accessible method for visualizing and measuring the deep muscles of the trunk<sup>(14, 53, 54, 61-64)</sup>. The value of ultrasound imaging from a rehabilitative perspective is that it allows for dynamic study (real-time images) of muscle groups as they contract. Consequently, the complementary use of ultrasound imaging can enhance the clinical analysis of the musculature system and has been advocated by various authors<sup>(3, 20, 65)</sup>. In addition to its clinical utility, numerous studies<sup>(7, 14, 19, 54, 61, 64, 66)</sup> have shown that ultrasound imaging is both a valid and reliable method to ascertain muscle size (through static quantitative measurements of muscle width, length, depth, CSA, or volume) and hence can be used as an indicator of muscle activity<sup>(14, 26)</sup>. Although, the interpretation process is complicated by the fact that the amount of change seen in a muscle's architecture during contraction does not necessarily represent the intensity or amount of actual muscle activity<sup>(14, 67)</sup>.

The RUSI technology is used both in clinical and research capacities and current physiotherapy applications including assessment of muscle morphology, architectural changes in muscles and associated structures with muscle activation, integrity of fascia, and motion of neurological tissue<sup>(14, 24)</sup>. In clinical setting, ultrasound imaging has been embraced in response to recent research which reveals that the primary impairment of the muscular system in individuals with low back pain is not one of strength or functional capacity but rather one of motor control of the deep muscles of the trunk<sup>(36, 39)</sup>. These deep muscles include the TrA, the deep segmental fibers of LM, the pelvic floor, and the diaphragm<sup>(3, 21, 37, 45)</sup>. The use of ultrasound imaging to observe the real-time contraction of muscles is a valuable tool,



as they are deep and not readily observable. RUSI serves to refine the accuracy of a clinician's palpatory and observational skills in detecting subtle contractions in muscles that are deep and difficult to directly access. Ability to image deep muscles is an advantage of the technique, and use of ultrasound imaging has been successfully incorporated in assessment and facilitation strategies for the TrA and LM muscles in low back pain patients.

RUSI apparatus for musculoskeletal imaging usually used multi-element transducers for determining the part of the body and the type of tissue being imaged<sup>(17, 24)</sup>. Straight linear and curvilinear array transducers are most commonly used. For linear transducer array, the ultrasound beams were all perpendicular to the line of transducers, and hence parallel to each other. The resulting rectangular field of view is useful in applications, where there is a need to image superficial areas of the body at the same time as organs at a deeper level. A curvilinear transducer gives a wide field at deeper levels. The depth that an ultrasound wave penetrates depends on its frequency, wavelength, as well as the properties of the medium or tissue it is traveling through. The new ultrasonography technologies, frequencies between 1 to 12 MHz are used. The lower frequencies are used when greater depths of imaging are required and the higher frequencies are used for visualizing more superficial structures. Furthermore, the higher the frequency of the source of the sound the less the emerging sound wave diverges. Consequently ultrasound waves are very cohesive (similar to a light beam leaving a laser pointer) and can be used to selectively expose a limited target area<sup>(17, 62)</sup>.

For imaging the LM muscle, a 5 MHz convex array transducer was found to be appropriate<sup>(68)</sup>. It produces a well defined image of the complex fascial



planes of this muscle. For imaging of the muscles of the abdominal wall, this transducer is also suitable. A linear array transducer is also suitable, and for larger patients a 3.5 MHz transducer can be used<sup>(17, 24)</sup>.

#### **1.2.4.1 Mode of Ultrasound image**

Two mode of ultrasound image are available: brightness mode (B-mode) and motion mode (M-mode)<sup>(62)</sup>. Basic principle of ultrasound image formation is used in B-mode system. B-mode image is a cross-sectional image representing tissues and organ boundaries within the body. Usually, the B-mode image bears a close resemblance to the anatomy, which might be seen by eye, if the body could be cut through in the same plane. Abnormal anatomical boundaries and alterations in the scattering behavior of tissues can be used to indicate pathology. Ultrasound imaging can be measured using calipers range from simple linear distance measurements to more complex volume measurements by digital electronics and software control<sup>(62)</sup>. The M-mode format provided real-time motion of tissues. To produce an M-mode display, the ultrasound beam is aligned with the moving target, and held in position by the operator (i.e. not scanned as in B-mode). M-mode image is shown as a wave pattern.

#### **1.2.4.2 Use of RUSI for assessment of musculoskeletal function**

The non-invasiveness of RUSI, user friendliness and speed and ease of application are all appealing features. There is now a focus in rehabilitation on the deep muscles that protect and support joints. RUSI could potentially be used to assist assessment and facilitation of various deep muscles of the body, including those of peripheral joints<sup>(3, 17, 24)</sup>. To implement this technique, the first step is to identify the normal cross-sectional anatomy. As there are several artifacts that can occur while

imaging, collaborative work between ultrasonographers and physiotherapists when exploring new areas is ideal. Also, due to the varying mechanics and orientation of muscle fascicles in different muscles, individual muscles will appear differently on imaging when they contract. For optimal benefit from imaging to be gained in rehabilitation for observing deep muscles, research into the best sites and techniques is required.

The use of RUSI can enhance the clinical assessment of musculoskeletal function and have been advocated by various authors.

Teyhen <sup>(7)</sup> studied the use of RUSI of the ADIM in subjects with LBP. Total LAM thickness (TrA, IO and EO) were measured in supine hook-lying position using ultrasound measurement with a 2- to 5- MHz curvilinear array. The musculoskeletal functions were calculated based on the relaxed and contracted stages of the abdominal muscle thickness. These contraction ratios were calculated to assess relative change of muscle thickness of TrA and oblique muscle groups. A preferential activation ratio was calculated to determine the relative coactivation of the TrA to the oblique muscle groups. This value measured the difference in the proportion of muscle thickness of the TrA relative to the total lateral abdominal muscle thickness at both the rested and contracted stages. A higher value represents a contraction with the majority of change in muscle thickness occurring in the TrA, while a lower or negative value represents greater relative change in muscle thickness of the oblique musculature. The study showed on average, patients demonstrated a 2-fold increase in the thickness of TrA during ADIM. The results of this study provide construct validity for notion that the ADIM results in preferential activation of the

TrA muscle and support its use as a foundational component for lumbar stabilization training programs.

Abdominal muscle function in chronic LBP patients was measured with real-time ultrasound scanning<sup>(13)</sup>. This study quantified the abdominal muscle thickness during low abdominal hollowing in four-point kneeling. Smaller increase in thickness of TrA in the patients than control was found. The study concluded that real-time ultrasound scanning was potentially a practical means of quantifying TrA performance.

Measurement of muscle size using ultrasound has provided an accurate assessment of muscle wasting and rehabilitation. For example, in acute LBP, RUSI demonstrated severe atrophy of LM muscle and was selective to the vertebral level on side of pain symptoms<sup>(25, 53, 69)</sup>. Moreover, it also demonstrated that LM muscle size does not recover when pain subsides unless it undergoes specific exercises<sup>(23)</sup>.

The relationship between levels of muscle activation and what is observed on the ultrasound image has been investigated by Hodges et al<sup>(14)</sup>. Comparison between EMG and ultrasound measurements revealed that the correlation was best for the deep TrA and least reliable for the superficial external oblique muscle. It is encouraging to know that linear measurements of increase in muscle thickness on ultrasound imaging (for the TrA and IO) correlated well with EMG activity. Ultrasound imaging is sensitive to the low-intensity contractions (less than 20-30% MVC) of TrA and IO that are generally used for assessment of LPS. This would suggest that a combination of ultrasound imaging for deep abdominal muscles

and surface EMG for the external oblique muscle would be optimal for research purpose.

### 1.2.5 Olympic-style weightlifting

Olympic-style weightlifting is a sport in which athletes attempt a maximum weight single lift of a barbell loaded with weight plates. Lifting heavy weight exposes the athletes to extreme force during both training and competitive events. Cholewicki et al <sup>(70)</sup> measured forces at the L4-L5 motion segment in 57 competitive weightlifters. The average compressive loads were more than 17,000 N. It has been suggested that weightlifting may predispose the athlete to spondylolysis <sup>(71-73)</sup> A 36.2% incidence of spondylolysis <sup>(74)</sup> was report in weightlifters. Injury reports at United State Olympic Training Centers showed that the low back was the most commonly injured area of the body in weightlifting (23.1%) <sup>(30)</sup>. The prevalence of LBP was shown to be even higher (41.67%) among Thai weightlifters <sup>(32)</sup>.

During weightlifting, many muscles are recruited and incorporated with good technique. It is suggested that an emphasis should be placed on achieving correct motor patterns before substantial weight is attempted. Young Eastern European athletes are reported to spend years developing form by lifting broomsticks. Only when their form is perfect do they add weight to the bar <sup>(75)</sup>. Preserving a neutral lumbar spine is thought to be essential for safe lifting <sup>(75)</sup>. In a study on the spinal biomechanics of power lifters, it was found that during the execution of a lift, L2-3 lumbar joints went into full flexion, while all other joints maintained their static position, resulting in 'buckling' of the spine and injury <sup>(76)</sup>. Protection and prevention of the spinal injury required more trunk muscles activation. Both segmental and global stabilization play important roles during lifting.

In routine weightlifting training programs, amount of significant weight is added after co-ordination and technique are correct<sup>(77)</sup>. Load should be increased gradually. Eventually, when the athlete can competently lift relatively heavy loads, target repetitions should be in the 3-5 per set range with loads of 85-95% of 1-RM<sup>(29, 78)</sup>. Normally, with exercises such as bench presses, dead lift, high pull and squats, loads in the region of 87-93% of 1-RM can be lifted for 3-5 repetitions. Peak power, however, is achieved with moderate, not maximal loads, executed with a fast tempo. By using a load of 75% of 1-RM (which would permit 10 repetitions with most traditional weight lifting exercises) and completing a maximum of 5 repetitions, proper form and speed of execution can be maintained. About 3-5 trials/set of each Olympic-style lift is adequate and rest intervals should be long enough to promote almost complete recovery between sets. Recommended rest interval time is 2-5 minutes<sup>(29, 77)</sup>.

In Olympic lifting programs, athletes practice 30-50 sets per day<sup>(29, 77)</sup>. Athletes must incorporate muscular strength, power, flexibility and balance in training. Several muscle groups utilize in lifting event such as leg muscles (quadriceps, hamstrings), back muscles (erector spinae, latissimus dorsi), upper extremities (deltoid, biceps and triceps). For example, snatch lifting is characterized by pulling the barbell upward to overhead with fully extended arm and dropping the trunk to distribute load to the knee then the trunk, arms and legs are fully extended while feet are kept in line. Snatch lifting required work of quadriceps muscle in the initial pull, then barbell is passed from knees to hips using back muscles. Finally, deltoid and scapular stabilizers muscles play dominant role to pull and lock the barbell. Weightlifters must keep the barbell closed to body and stabilize it overhead to

complete lifting. Therefore, lumbopelvic stabilization is needed to keep erect posture which requires deep muscles included TrA and multifidus for local segment stability and superficial muscles such as IO and EO for global stability.

### 1.3 Purposes of the study

The main purposes of the entire study were to investigate the role of deep trunk muscles on lumbopelvic stability among Thai weightlifters.

Specific aims were:

- 1) to determine intrarater reliability, and interrater reliability of LAM thickness and CSA of LM muscles measurements using B-mode ultrasound.
- 2) to compare LAM thickness between weightlifters and matched controls.
- 3) to investigate the characteristics of LAM in elite female weightlifters.
- 4) to investigate the thickness and the contraction ability of TrA muscle among elite female weightlifters with and without LBP.
- 5) to compare the CSA and symmetry of the LM muscles among elite weightlifters with and without LBP.
- 6) to investigate the contraction ratio of the LM muscles in elite weightlifters with and without LBP.



#### **1.4 The organization of the thesis**

The thesis consists six chapters. Rationale, background and aims of the studies are presented in chapter 1. Reliability of LAM and LM muscles measurements using B-mode ultrasound are provided in chapter 2. Main studies are presented in chapter 3 and 4. Chapter 3 presents the result of the LAM thickness, contraction ability and its characteristics among weightlifters with and without LBP. Chapter 4 presents the results of CSA and the contraction ratio of the LM muscles among elite weightlifters with and without LBP. All results are concluded in chapter 5. Finally, references are shown in chapter 6.