

ภาคผนวก ก

ตัวอย่างแบบประเมินผล

**Questionnaire**

**Notice:** This questionnaire is the part of independent study for Development of an Expert Model System for Consultation on Possible Cures for Open Fractures of the Upper and Lower Extremities for General Practitioners at Somdej Prajao Taksin Maharaj Hospital, Tak Province for Master degree of science (Information technology and management)

**Objective:** For efficiency of the Development of an Expert Model System for Consultation on Possible Cures for Open Fractures of the Upper and Lower Extremities for General Practitioners at Somdej Prajao Taksin Maharaj Hospital, Tak Province for Master degree of science (Information technology and management)

By Polawat Witoolkollachit

Code: 4640348

**General Information:**

1. How old are you?
  - a. 20-30 yrs
  - b. 30-40 yrs
  - c. 40-50 yrs

2. What is your specialty?

- a. General practice
- b. Orthopaedic Surgeon

**Program Performance:**

**User interfaces:**

1. What do you think about the user inferface?
  - a. Best
  - b. Good
  - c. Fair
  - d. Bad

**Process complexity:**

1. Is it complicate?
  - e. Not at all
  - f. Easy
  - g. Fair
  - h. More complicate
  - i. Hard to understand

**Result form this system:**

**Answer: (Open fracture type, Rx)**

1. A 10 years old boy had suffering from the failing down accident. He had 1 cm. wound at the front of the tibia. The surrounding soft tissue was slightly contusion. x-ray found the incomplete fracture of the mid shaft of the tibia.

**Answer :**.....

2. A 21 years old male had the motorcycle accident last night. He had large laceration about 11 cm in length. The wound wasn't in good condition. The neuro-vascular were good. But the tibia protruded through the wound.

**Answer :**.....

3. A 32 years old female had an accident in her pig farm while washing the pig fecal material. She had a small wound(less than 1 cm.). The x-ray had shown the fracture of the middle shaft of the ulnar.

**Answer :**.....

4. A 34 years male had a car accident. He drove it into the canal. He has a 5 cm wound on his right thigh. The wound had a very small amount of debris. He had some bleeding from it. The x-ray had shown fracture of the femur with minimal comminution.

**Answer :**.....

5. 42 years old female had a cut wound at his right arm with 6 cm. long. The forearm was pale color and slightly cold. She couldn't extend her wrist. The x-ray shown simple transverse fracture of the shaft humerus.

**Answer :**.....

6. 20 years old man, while playing the football. He was hit by his friend. He had the 2 cm. wound on his leg. The wound look good. The X-ray had shown small amount of comminution.

**Answer :**.....

7. 51 years old male had an accident from motorcycle. He had the deformed thigh and 2 wounds. The frist wound was 3 cm in length and the last was 7 cm. on the other side. The X-ray had shown severe comminuted fracture of femoral.

**Answer :**.....

8. 16 yeas old hill tribe female had the motorcycle accident 2 days ago. She had 2 cm wound at the left leg. The x-ray had shown simple trasverse fracture of tibial.

**Answer :**.....

9. 39 years old male had gunshot wound injury from Thailand border. He had 2 cm round wound at his thigh, The x-ray shown no bullet in the thigh but his leg became large and his leg was cold. The fracture was simple transverse.

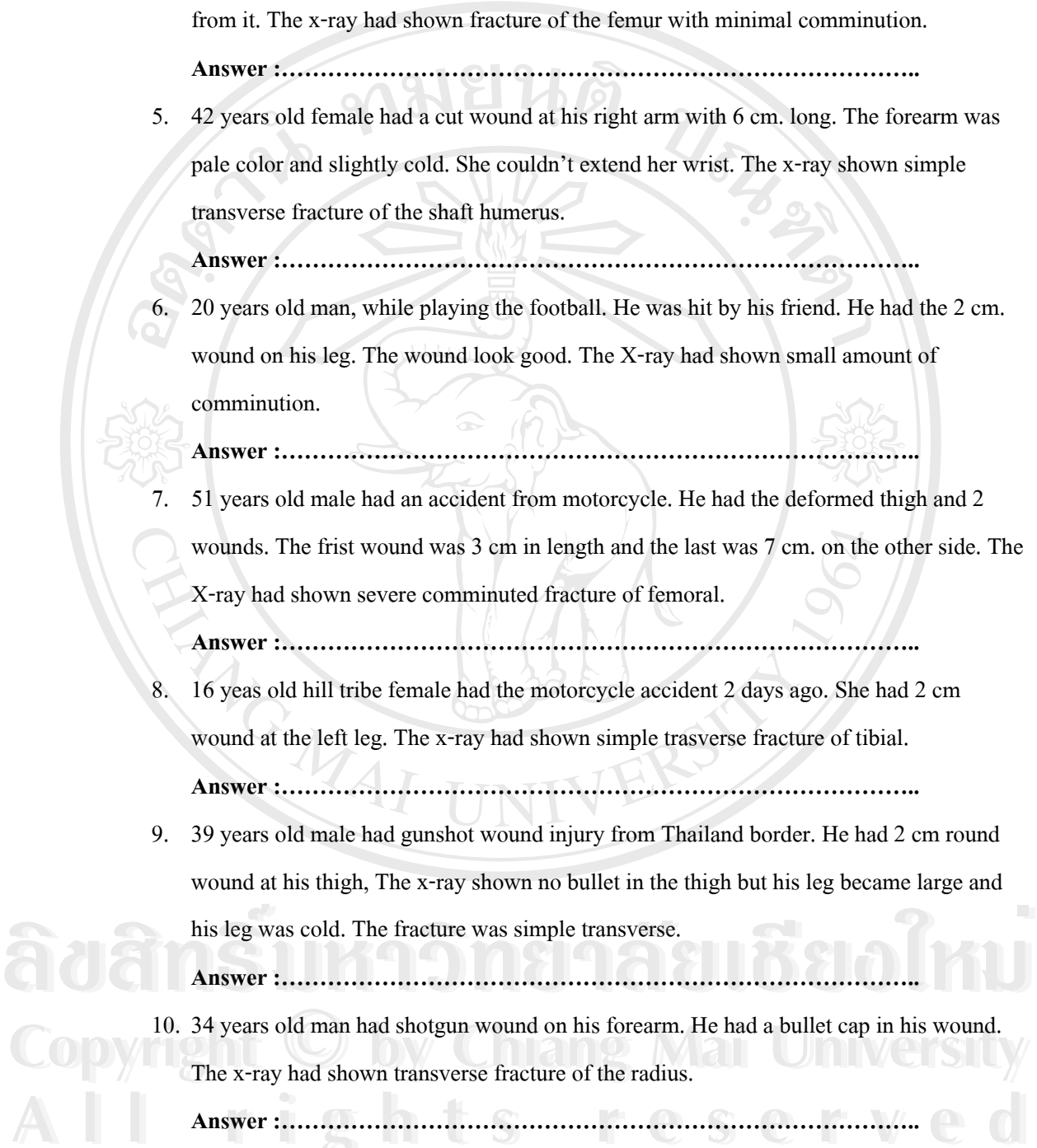
**Answer :**.....

10. 34 years old man had shotgun wound on his forearm. He had a bullet cap in his wound. The x-ray had shown transverse fracture of the radius.

**Answer :**.....

11. 17 Years old male had a car accident. He had 15 cm, wound on his left leg. The periostium and skin were lost. The tibail bone was protruded to the wound. The neuro and vascular were OK.

**Answer :**.....



12. 51 years old male had an accident from motorcycle. He had the deformed thigh and 2 wounds. The frist wound was 9 cm in length and the last was 5 cm. on the other side. The x-ray had shown moderate comminuted fracture of femoral.

**Answer :**.....

13. A 34 years male had a car accident. He drove it into the drainage pool. He has a 1 cm wound on his right thigh. The wound had a very small amount of debris. He had some bleeding from it. The x-ray had shown fracture of the femur with minimal comminution.

**Answer :**.....

14. A 15 years old male had the motorcycle accident last night. He had large laceration about 11 cm in length on his left leg. The wound wasn't in good condition. The neuro-vascular were good.

**Answer :**.....

15. A 31 years old male had the motorcycle accident last night. He had large laceration about 11 cm in length. The wound wasn't in good condition. The neuro-vascular were good. But the tibia protruded through the wound.

**Answer :**.....

16. 18 yeas old hill tribe female had the motorcycle accident 8 hrs ago. She had 2 cm wound at the left leg. The x-ray had shown simple transverse fracture of tibial.

**Answer :**.....

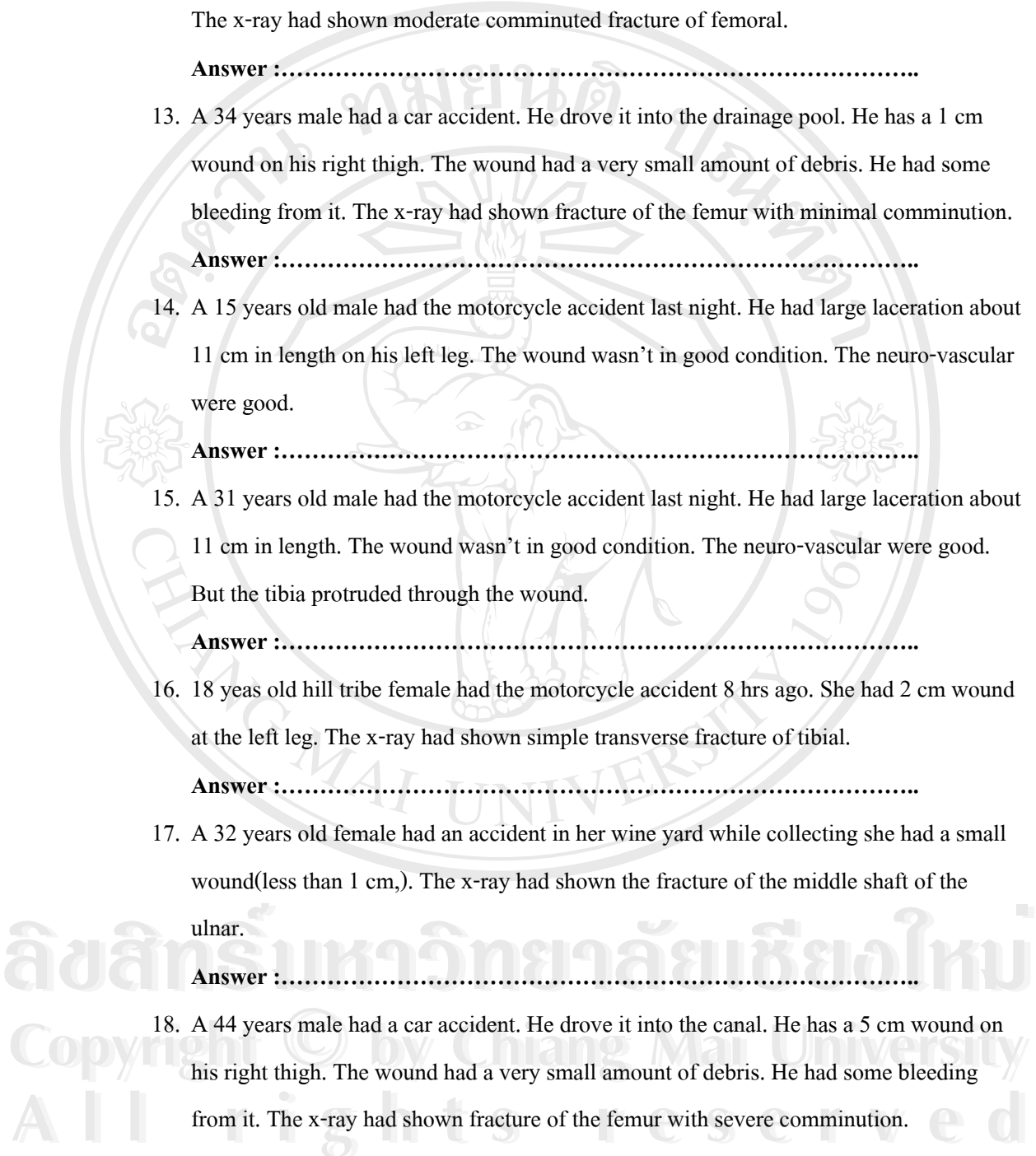
17. A 32 years old female had an accident in her wine yard while collecting she had a small wound(less than 1 cm,). The x-ray had shown the fracture of the middle shaft of the ulnar.

**Answer :**.....

18. A 44 years male had a car accident. He drove it into the canal. He has a 5 cm wound on his right thigh. The wound had a very small amount of debris. He had some bleeding from it. The x-ray had shown fracture of the femur with severe comminution.

**Answer :**.....

19. A 35 years old male had the motorcycle accident last night. He had large laceration about 18 cm in length. The wound wasn't in good condition. The neuro-vascular were good.



But the tibia protruded through the wound.

**Answer :**.....

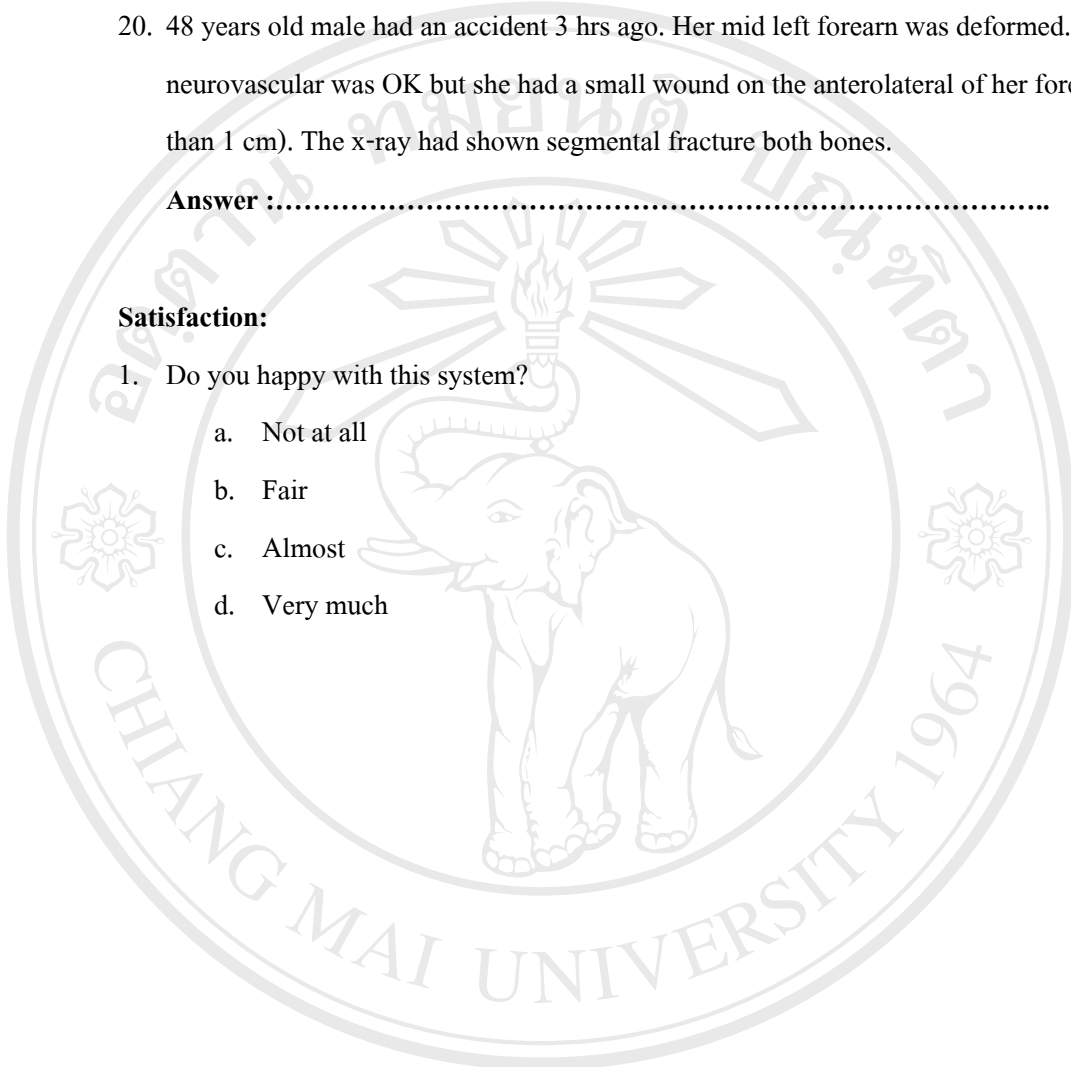
20. 48 years old male had an accident 3 hrs ago. Her mid left forearn was deformed. The neurovascular was OK but she had a small wound on the anterolateral of her forearm(less than 1 cm). The x-ray had shown segmental fracture both bones.

**Answer :**.....

**Satisfaction:**

1. Do you happy with this system?

- a. Not at all
- b. Fair
- c. Almost
- d. Very much



ภาคผนวก ข

ใบเสร็จค่าโปรแกรม CLPIS ActiveX for Windows Education Edition

**Athena Information Services, Inc**

P.O. Box 621888  
Oviedo, FL 32762-1888  
E-Mail at athenainfvcs@hotmail.com  
Website www.athenainfvcs.com

Invoice No. RE11949596

**Invoice**

**Customer**

Name Polawat Witoolkollachit  
Address 356 Taksin Rd  
City Tumbon Nonglueng, Muang Tak 63000  
Country Thailand

Date 4/11/2005  
Order No.  
Rep  
FOB

Qty	Description	Unit Price	TOTAL
1	CLIPS ActiveX for Windows Educational Edition	\$39.95	\$39.95
SubTotal			\$39.95
Shipping & Handling			
Taxes			
TOTAL			\$39.95

**Payment Details**

- Cash  
 Check  
 Credit Card

Name \_\_\_\_\_  
cc# \_\_\_\_\_ Expires \_\_\_\_\_

*Paid in Full*

ลิขสิทธิ์มหาวิทยาลัยเชียงใหม่  
Copyright © by Chiang Mai University  
All rights reserved

## ประวัติผู้เขียน

- ชื่อ นายพลววรรณ วิฑูรกลชิต
- วัน เดือน ปีเกิด 28 มกราคม 2512
- ประวัติการศึกษา  
แพทยศาสตรบัณฑิต คณะแพทยศาสตร์  
มหาวิทยาลัยเชียงใหม่  
ปีการศึกษา 2534-2535  
ประกาศนียบัตรชั้นสูงด้านวิทยาศาสตร์การแพทย์ (ศัลยกรรม)  
มหาวิทยาลัยมหิดล  
ปีการศึกษา 2536  
วุฒิปัตริ์ผู้เชี่ยวชาญด้านกระดูกและข้อ (เวชวิทยบาล) แพทยสภา  
ปี 2539
- ประสบการณ์  
พ.ศ. 2535 นายแพทย์ 4  
รพ.ศ. ขอนแก่น จ.ขอนแก่น  
พ.ศ. 2537 นายแพทย์ 5  
รพ.สมเด็จพระเจ้าตากสินมหาราช จ.ตาก  
พ.ศ. 2540 นายแพทย์ 6  
รพ.สมเด็จพระเจ้าตากสินมหาราช จ.ตาก  
พ.ศ. 2542-ปัจจุบัน นายแพทย์ 7  
ผู้เชี่ยวชาญด้านเวชกรรม(ศัลยศาสตร์ออร์โธปิดิกส์)  
รพ.สมเด็จพระเจ้าตากสินมหาราช จ.ตาก